


PATIENT

Ginger Adams

PRESENTING CLINICAL SIGNS

 History: Recheck echo. Grade 4-5/6 bilateral murmur.
 -Current medications: Benazepril 5mg BID, furosemide 10mg BID, Vetmedin 2.5mg BID
 -Pertinent previous echo findings (6/2021 MML): Severe MR, severe LAE, mild LVE, mild RHE, mild TR: 2.2m/s. LA: 2.8, LV: 3.7.

SPECIES

Canine

ECHOCARDIOGRAM FINDINGS

2D, m-mode, color flow and doppler imaging is available. The mitral valve is diffusely thickened with prolapse into the left atrial lumen. There is severe eccentric mitral regurgitation present. The MR velocity is normal. There is severe left atrial enlargement. There is mild left ventricular dilation. Left ventricular systolic function is hyperdynamic. Mild right atrial and ventricular dilation (subjective). Mild thickening of the tricuspid valve with mild TR. Normal velocity. The aortic valve appears trileaflet with normal mobility. Mildly elevated aortic outflow velocity. The main pulmonary artery is normal in diameter. The pulmonic valve is normal in appearance. No pericardial/pleural effusion or cardiac masses are seen.

BREED

Minature Dachshund

SEX

Female Spayed

AGE

10 years

CARDIAC CHART
WEIGHT

15lbs

INTERPRETED BY

 Maggie Machen Lamy,
 DVM DACVIM
 (Cardiology)

IMAGING
PERFORMED BY

Kelly Reschny, RVT

HOSPITAL NAME

 Maples Animal
 Hospital

REFERRING VET

Dr. Kazienko

CANINE CARDIAC PARAMETERS	MR VMAX (m/s)	TR VMAX (m/s)	LA/AO (Boon method)	LA/AO (Heart Base; Swe)	FS (%)	EF (%)	EPSS (cm)
NORMAL PARAMETER	4.5-5.5	<2.7	1.3	<1.6	28-40	40-100	<0.6
PATIENT	5.4	2.0	1.5	2.5	50	83	NM
CANINE CARDIAC PARAMETERS	HR (BPM)	AV VMAX (m/s)	PV MAX (m/s)	BODY WEIGHT (kg)	LA 2D short axis Base view (cm)	LVIDd Avg; 2D and m-mode short axis (cm)	LVIDs Avg; 2D and m-mode short axis (cm)
NORMAL PARAMETER	50-100	0.7-1.7	0.7-1.6	BELOW	BELOW	BELOW	BELOW
PATIENT	200	2.5	2.0	6.8	2.8	3.8	1.7
*Normal chamber parameters expressed as a mean value (SD)				3	1.27 (5.3)	2.46 (2.46)	1.36 (5.5)
BODY WEIGHT DEPENDENT PARAMETERS				5	1.40 (4.5)	2.74 (5.2)	1.60 (4.7)
<i>*Note: All measurements based upon multi-modal images and methods. An average value is reported.</i>				10	1.50 (3.8)	3.27 (3.5)	2.06 (3.1)
				15	1.83 (2.0)	3.71 (2.4)	2.43 (2.1)
				20	2.02 (1.9)	4.14 (2.2)	2.80 (2.0)
				25	2.18 (2.4)	4.48 (2.9)	3.10 (2.5)
				30	2.33 (3.3)	4.83 (3.9)	3.39 (3.4)
				35	2.48 (4.3)	5.17 (5.0)	3.69 (4.5)
				40	2.62 (5.2)	5.48 (6.1)	3.96 (5.4)
				50	2.88 (7.1)	6.07 (8.3)	4.46 (7.4)

INTERPRETATION OF THE FINDINGS & FURTHER RECOMMENDATIONS

Chronic degenerative valve disease persists without significant progression. Severe mitral and mild tricuspid regurgitation are similar to previous with stable yet significantly dilated left heart dimensions. No pulmonary hypertension or other comorbidities have developed.

INVOICE

22184

DATE

11/28/21



PATIENT

Ginger Adams

Given these findings, continue cardiac supportive medications as below. Lasix is being utilized without explanation; if CHF was documented previously this should be continued. Spironolactone remains recommended for long-term anti-fibrotic benefits.

SPECIES

Canine

Prognosis remains guarded at this stage (late B2/C). Unfortunately, the patient will remain at risk for recurrent CHF, development of arrhythmias/LA tear, syncope and/or sudden death in the future.

BREED

Minature Dachshund

Close monitoring for development of associated clinical signs (development of a cough, labored breathing, exercise intolerance or worsening collapse episodes) is recommended. Monitoring of sleeping breathing rates is recommended as the best way to screen for CHF at home.

SEX

Female Spayed

Elective anesthesia is not advised.

AGE

10 years

Omega fatty acid supplementation and mild salt restriction may also be of some long-term benefit.

PLAN

WEIGHT

15lbs

A screening BP is recommended every 6 months. Continue Pimobendan and Benazepril as prescribed. Institute spironolactone 1-2mg/kg PO q12h. IF CHF has been documented previously, continue Lasix as prescribed.

Monitor renal values every 3-4 months lifelong to ensure tolerance of medications.

INTERPRETED BY

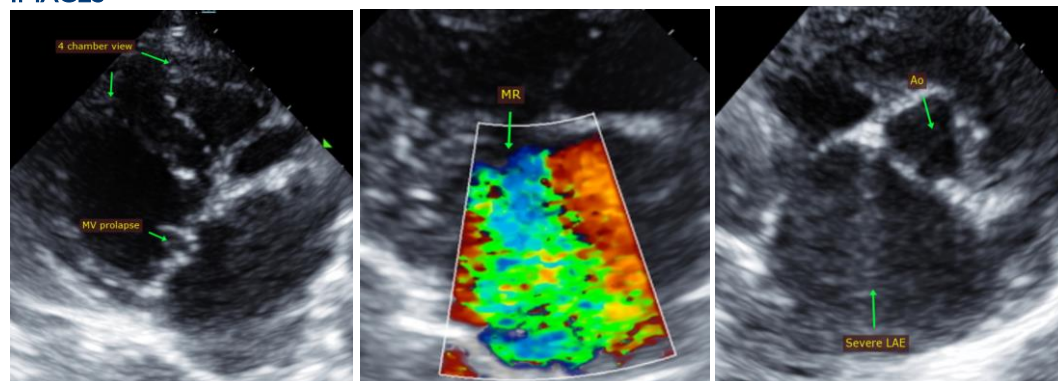
Maggie Machen Lamy,
DVM DACVIM
(Cardiology)

A recheck echocardiogram is recommended in 6 months to screen for progression, sooner if clinical signs arise.

IMAGES

IMAGING PERFORMED BY

Kelly Reschny, RVT



HOSPITAL NAME

Maples Animal Hospital

REFERRING VET

Dr. Kazienko

INVOICE

22184

DATE

11/28/21



PATIENT

Ginger Adams

The information and recommendations provided are based on the images presented by the referring veterinarian. No evaluation can be communicated regarding pathology that was not visible in the image/video clips provided.

SPECIES

Canine

Thank you for this referral. This report was generated using transcription software, and minor dictation errors may be present. If the clinical or image interpretation does not parallel your findings or if I can be of any further assistance, please contact me.

BREED

Minature Dachshund

Maggie Machen Lamy, DVM
Diplomate of the American College of Veterinary Internal Medicine (Cardiology)
info@sonopath.com

SEX

Female Spayed

AGE

10 years

WEIGHT

15lbs

INTERPRETED BY

Maggie Machen Lamy,
DVM DACVIM
(Cardiology)

**IMAGING
PERFORMED BY**

Kelly Reschny, RVT

HOSPITAL NAME

Maples Animal
Hospital

REFERRING VET

Dr. Kazienko

INVOICE

22184

DATE

11/28/21